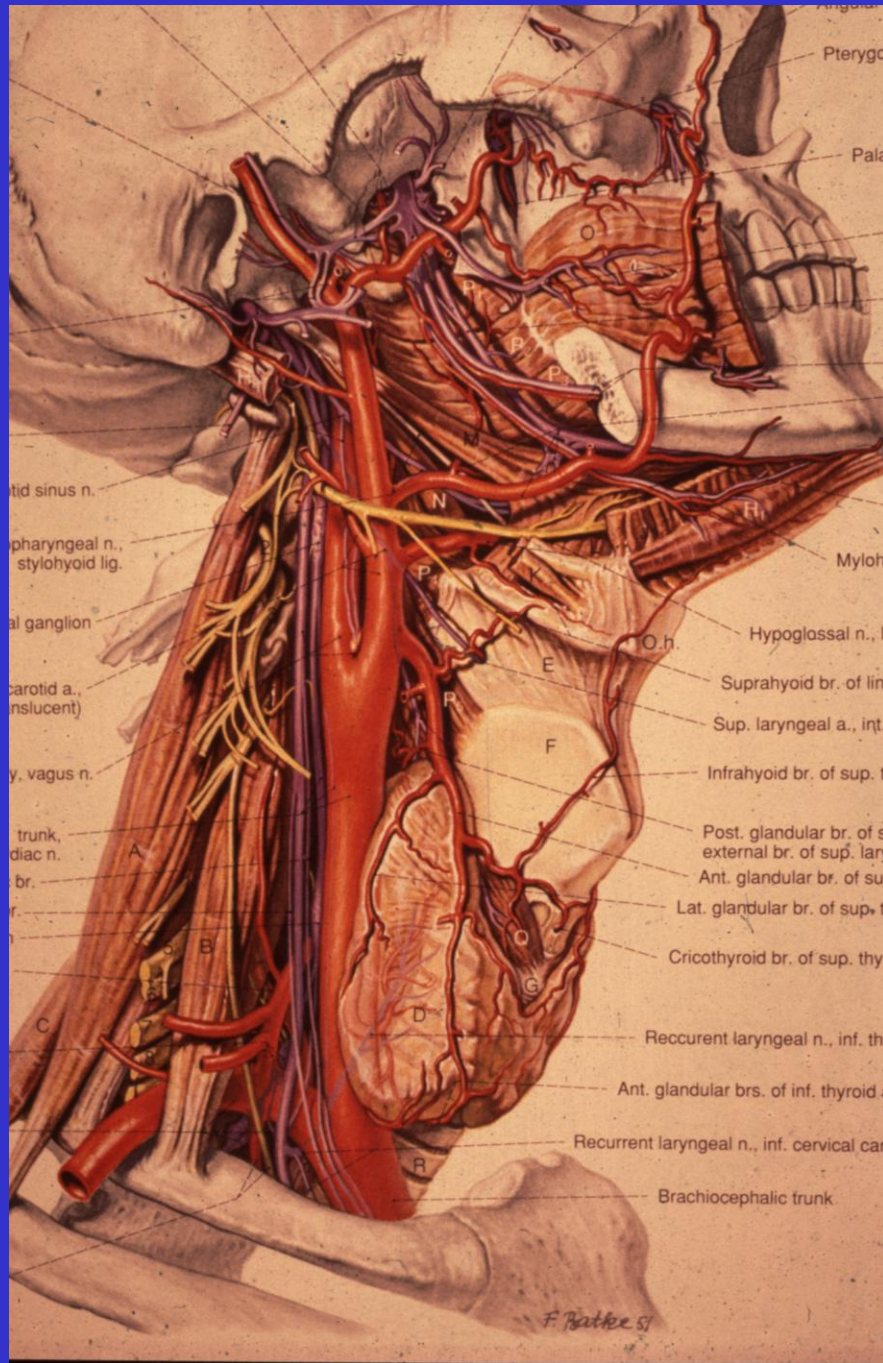

tid sinus n.

pharyngeal n.,  
stylohyoid lig.

al ganglion

carotid a.,  
(insolvent)

y, vagus n.

trunk,  
diac n.

br.

r.

n.

n.

n.

n.

n.

n.

n.

n.

n.

n.

n.

n.

n.

n.

n.

Pterygo

Pala

Mylohy

Hypoglossal n., li

Suprahyoid br. of ling

Sup. laryngeal a., int.

Infrahyoid br. of sup. th

Post. glandular br. of s

external br. of sup. lary

Ant. glandular br. of sup

Lat. glandular br. of sup. th

Cricothyroid br. of sup. thyr

Recurrent laryngeal n., inf. thy

Ant. glandular brs. of inf. thyroid a

Recurrent laryngeal n., inf. cervical car

Brachiocephalic trunk

F. Peck 57

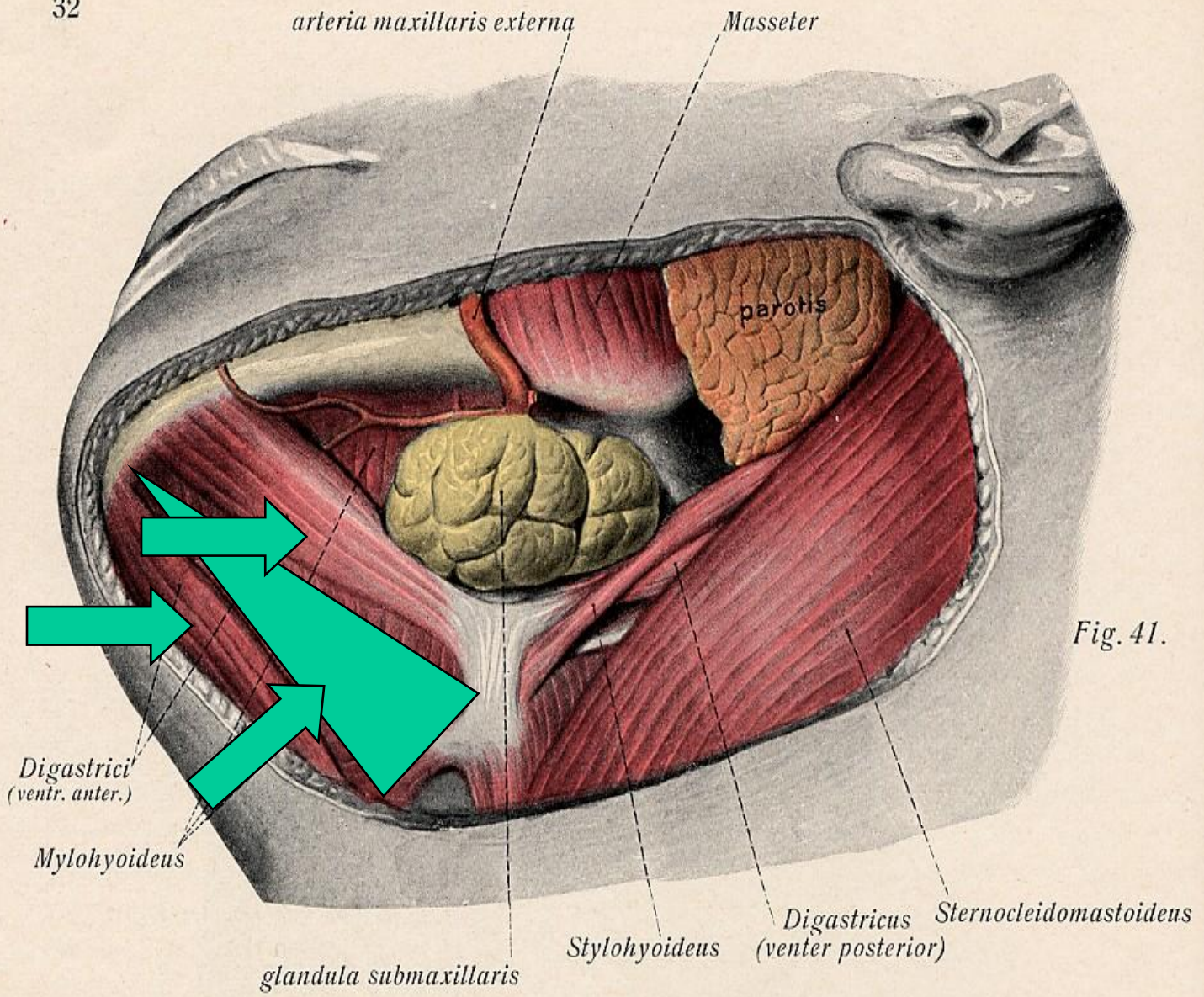


Fig. 41.

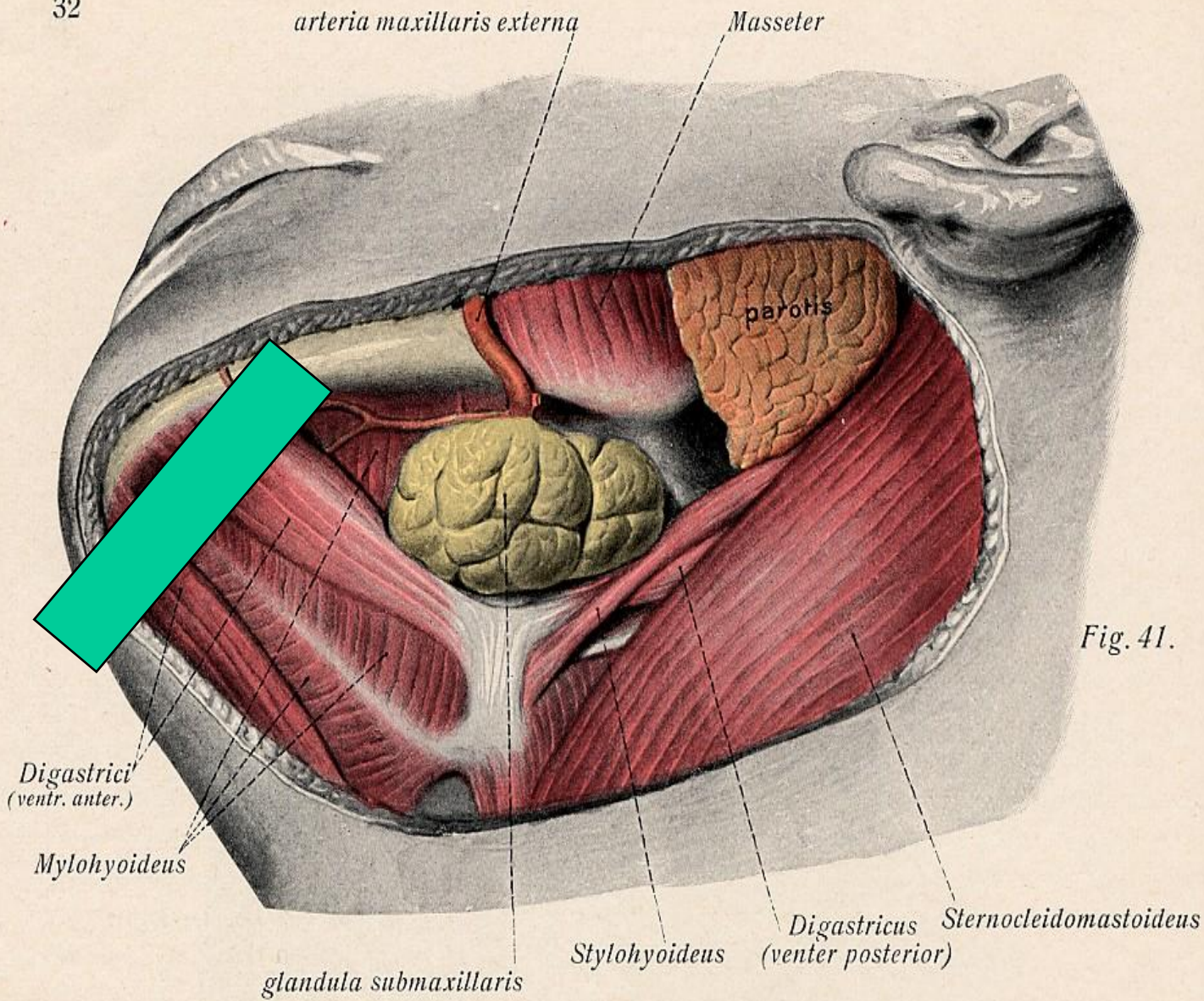
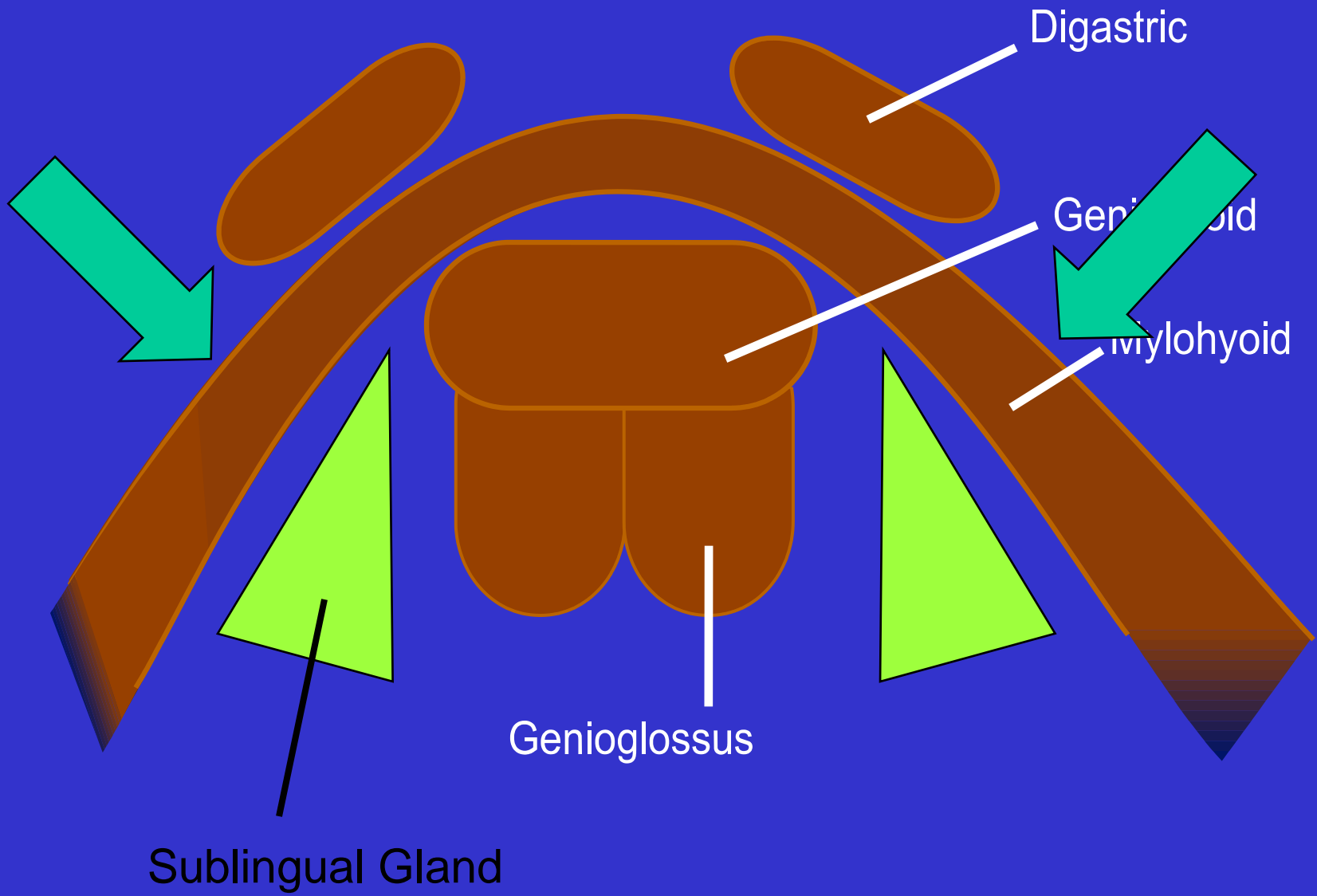


Fig. 41.



Digastric

Geniohyoid

Mylohyoid

Genioglossus

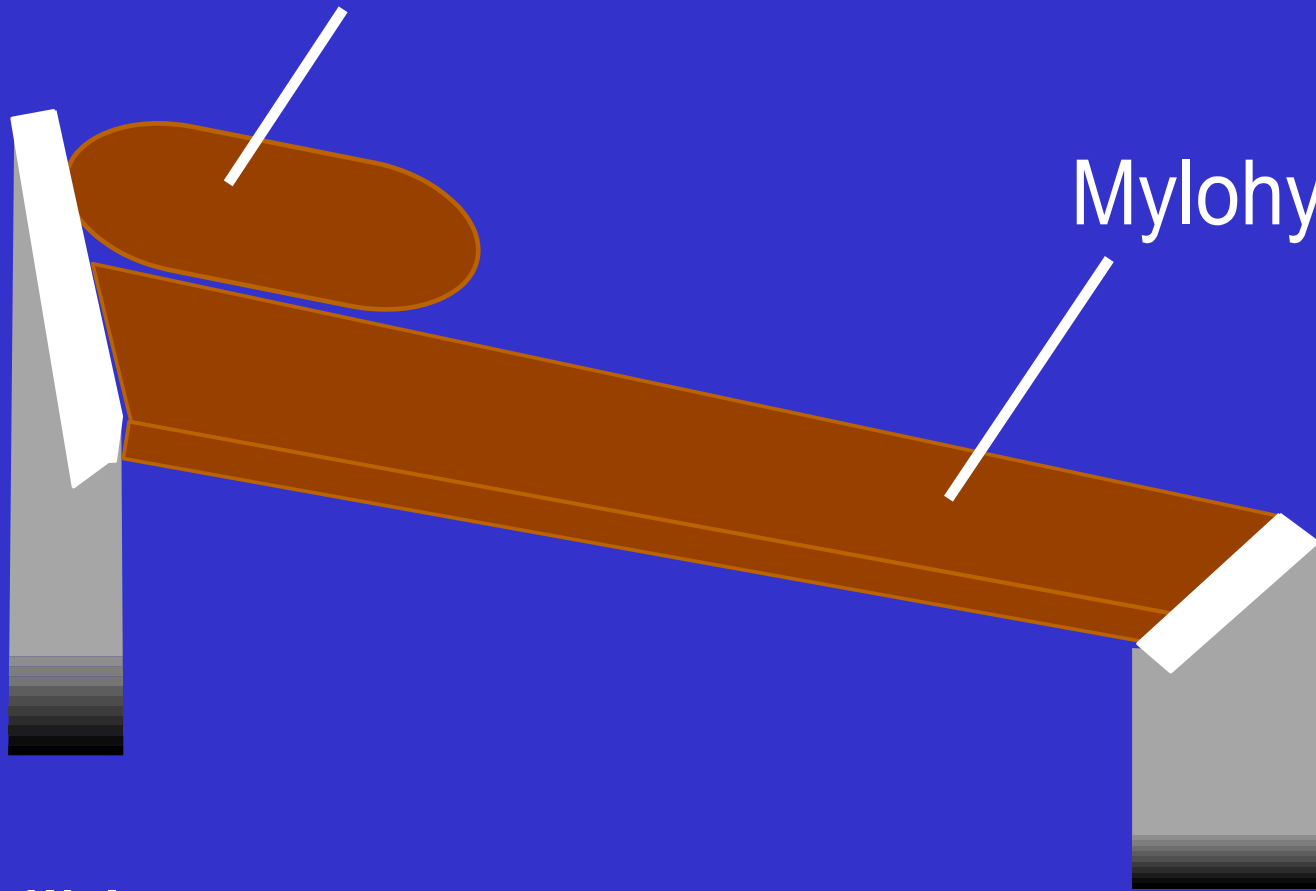
Sublingual Gland

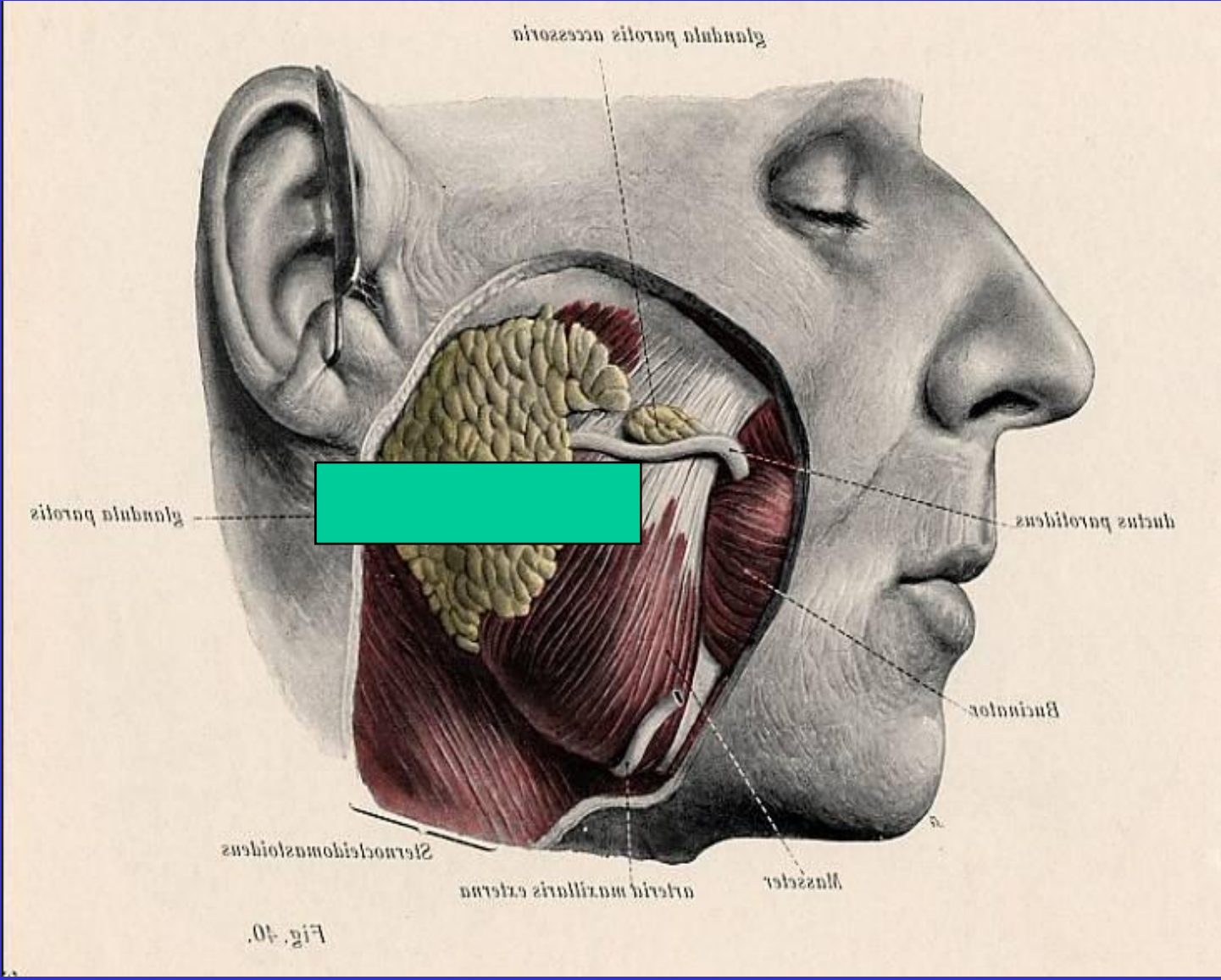
Digastric

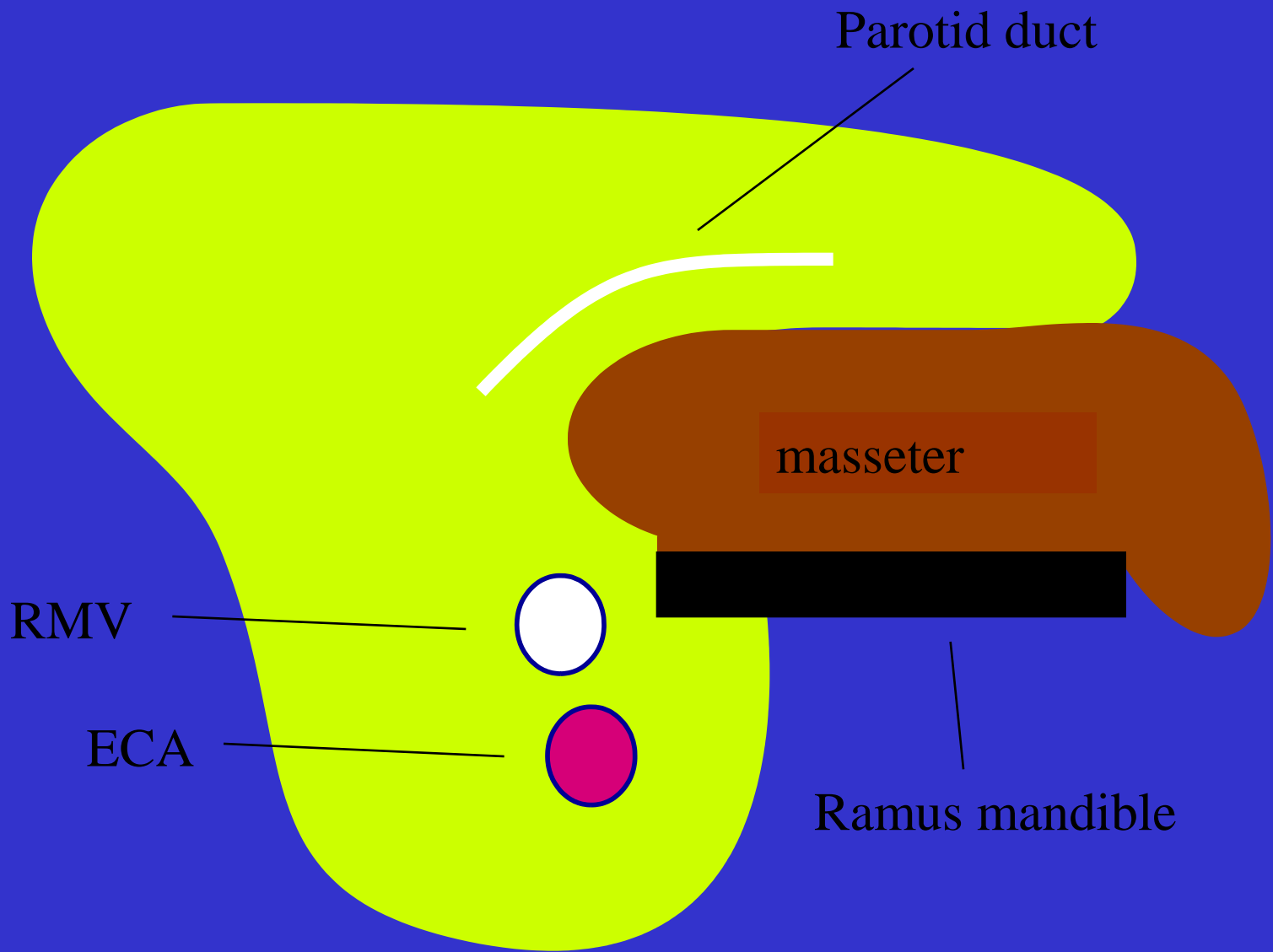
Mylohyoid

Mandible

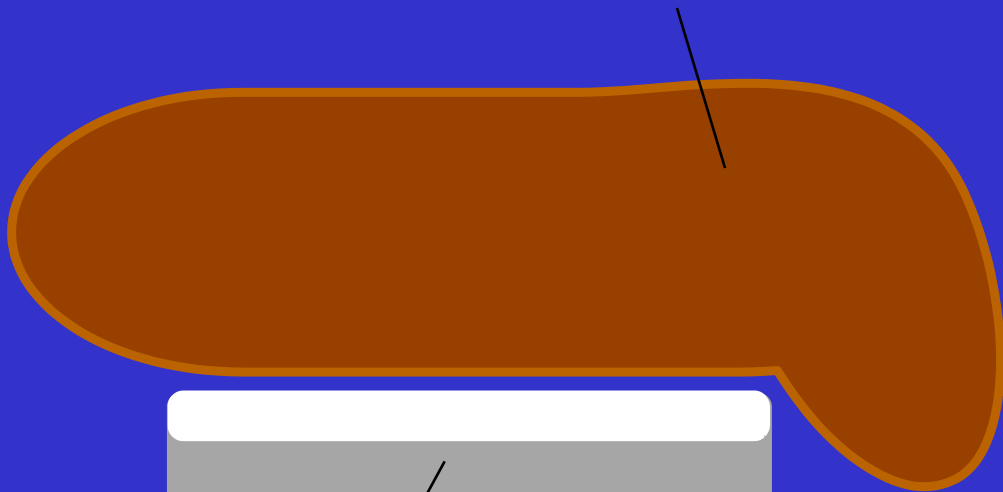
Hyoid










masseter



Facial artery



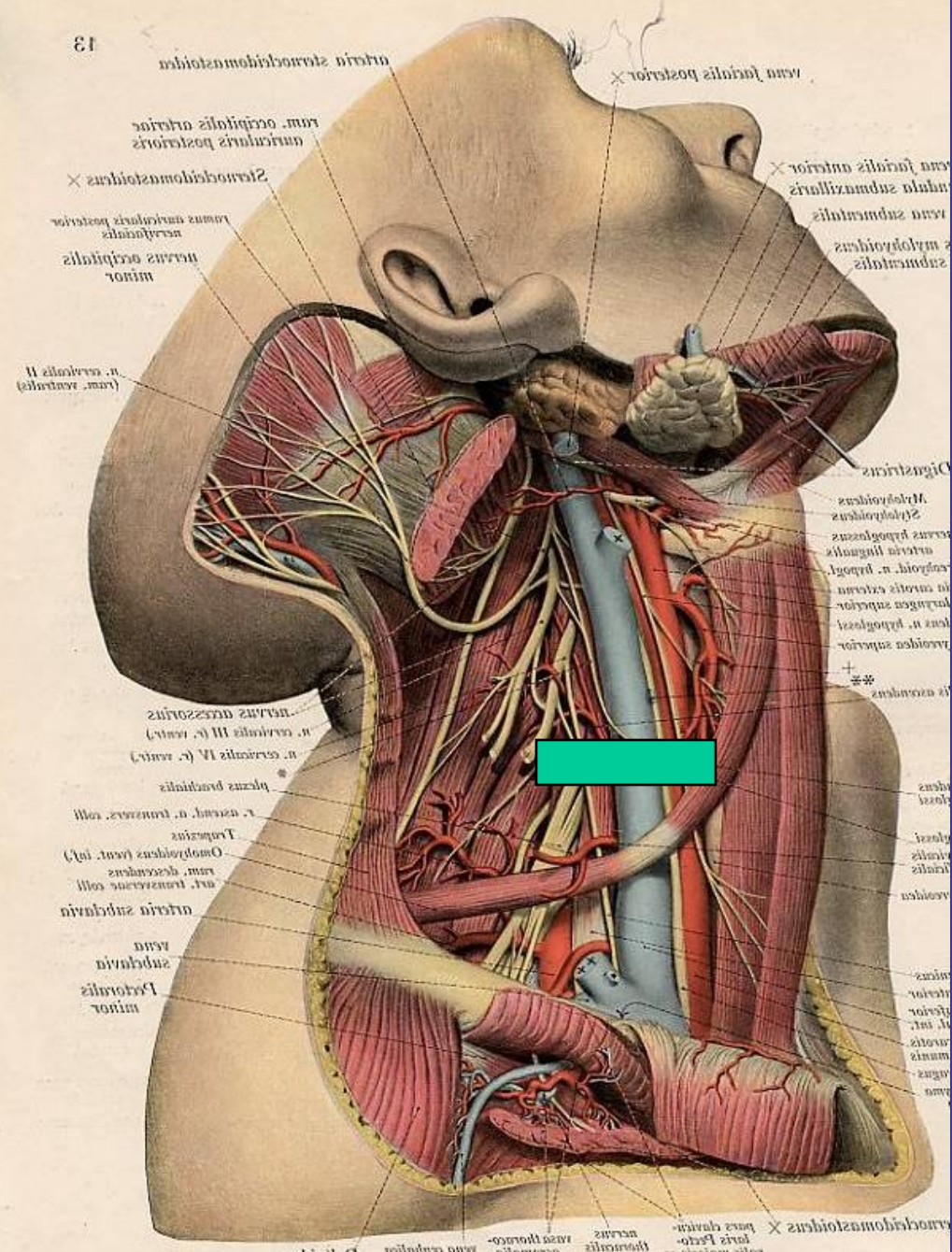
mandible



mucosa

buccinator





arteria sternocephalica  
 vena facialis posterior  
 ram. occipitalis arteriae  
 muscularis posterior  
 Sternocephalica  
 ramus anterior posterior  
 nervus occipitalis  
 minor  
 n. cervicalis II  
 (ram. ventralis)

vena facialis anterior  
 vena subclavia  
 musculi  
 subclavi

nervus accessorius  
 n. cervicalis III (r. ventr.)  
 n. cervicalis IV (r. ventr.)  
 plexus brachialis  
 r. cervic. n. truncus coll.  
 Truncus  
 Omphalocephalus (vent. inf.)  
 ram. descendens  
 n. transversus coll.  
 arteria subclavia  
 vena  
 subclavia  
 Portio minor

Digastricus  
 Mylohyoideus  
 Stylohyoideus  
 Cervicohyoideus  
 Arteria lingualis  
 Arteria n. thyroidei  
 In arteria externa  
 Laryngis superior  
 Vena n. thyroidei  
 Vena superior

arteria sternocephalica  
 pars dorsalis  
 pars thoracica  
 nervus  
 vena thoracica  
 thoracica  
 vena cervicalis  
 vena cephalica

Sternomastoid





Omohyoid




Common Carotid Artery



Lymph Nodes

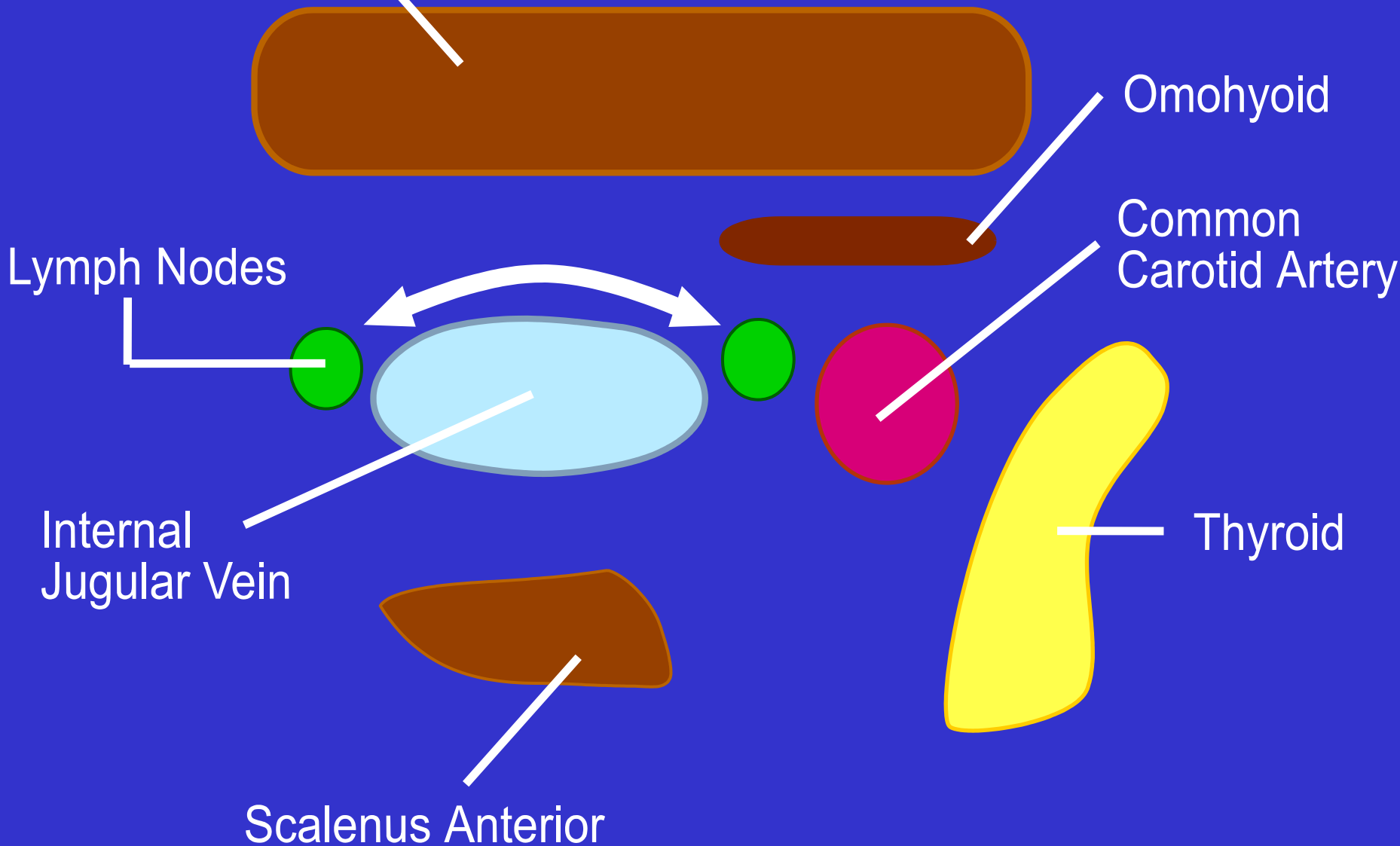


Internal Jugular Vein



Scalenus Anterior

Thyroid



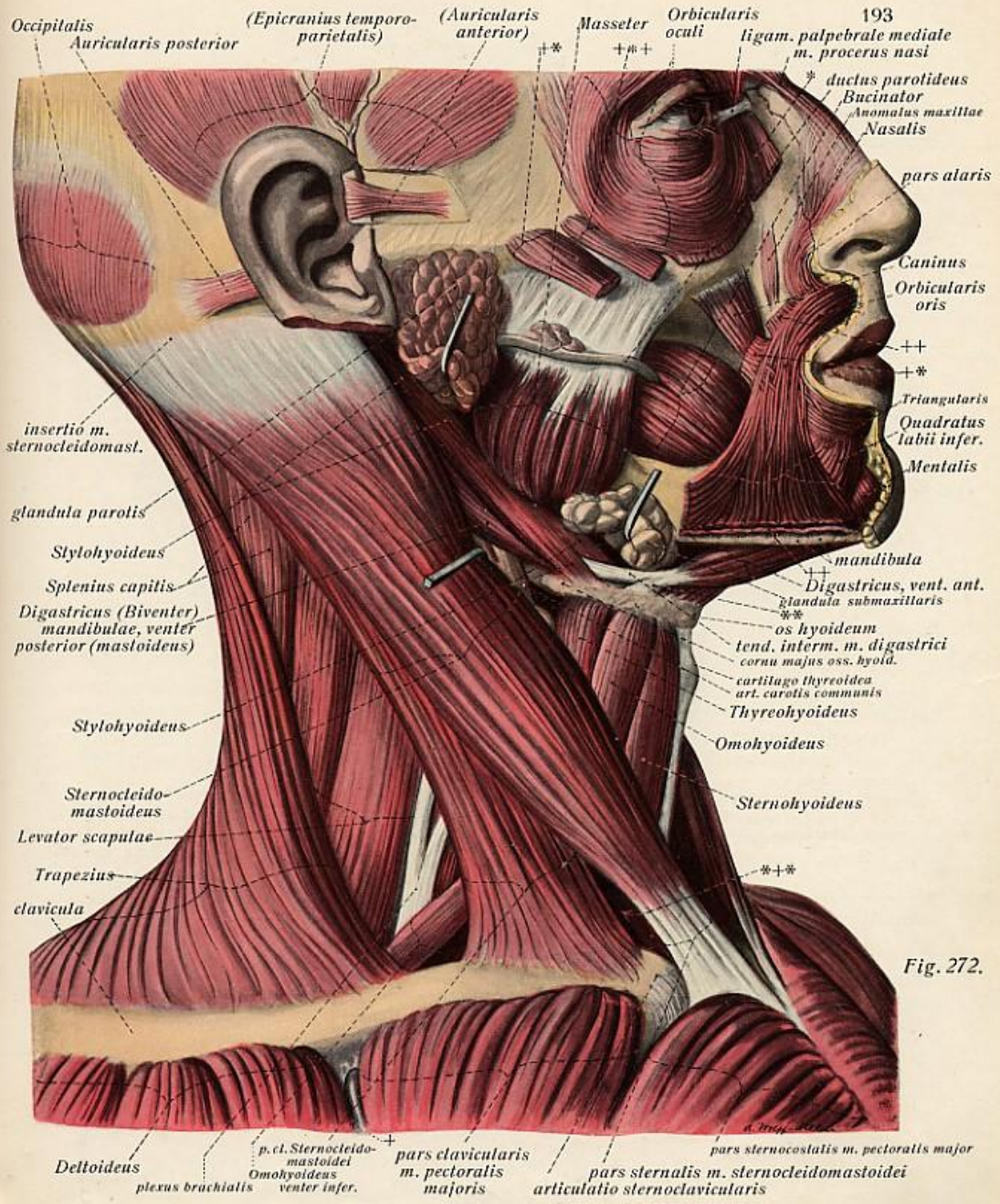


Fig. 272.

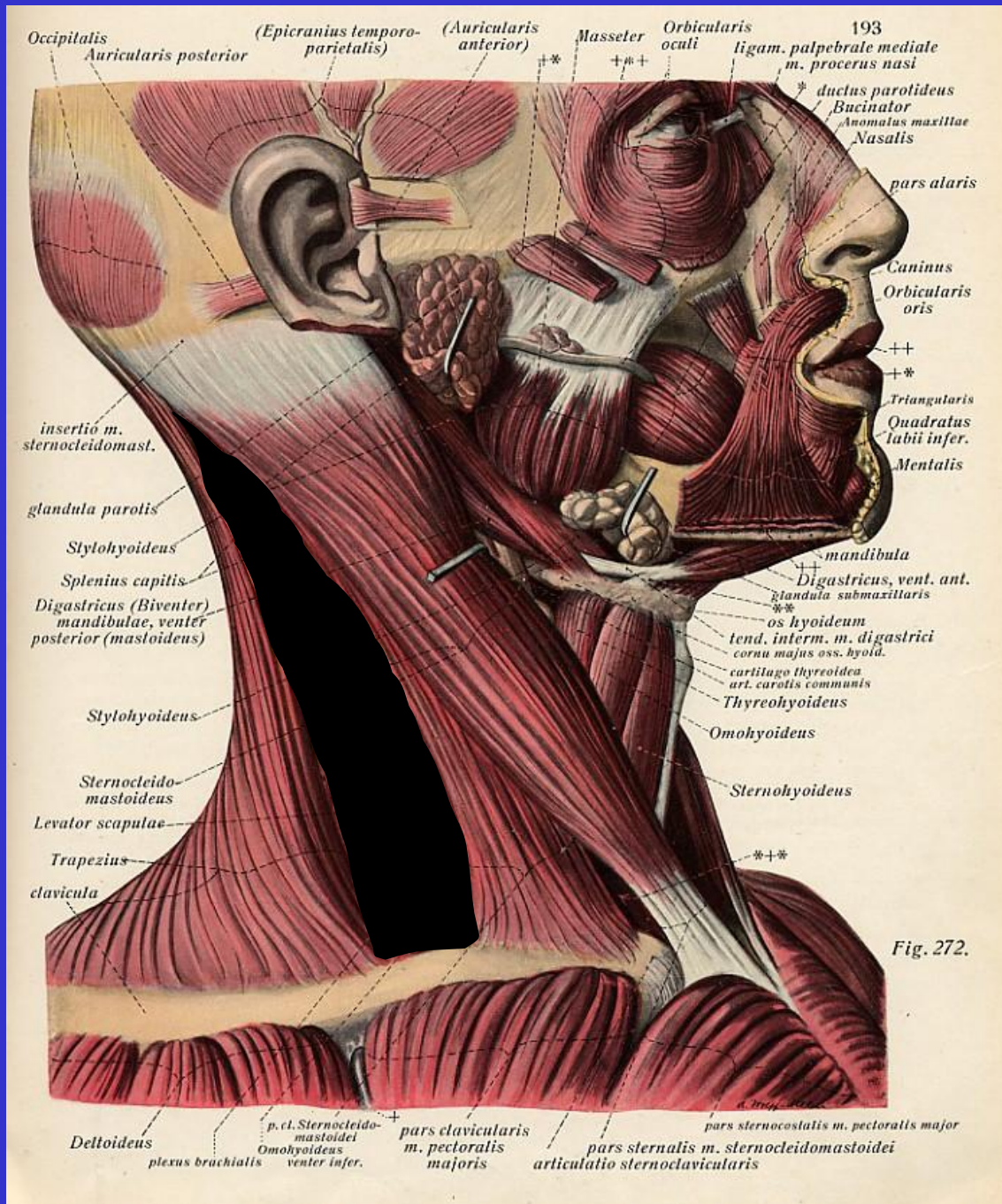


Fig. 272.

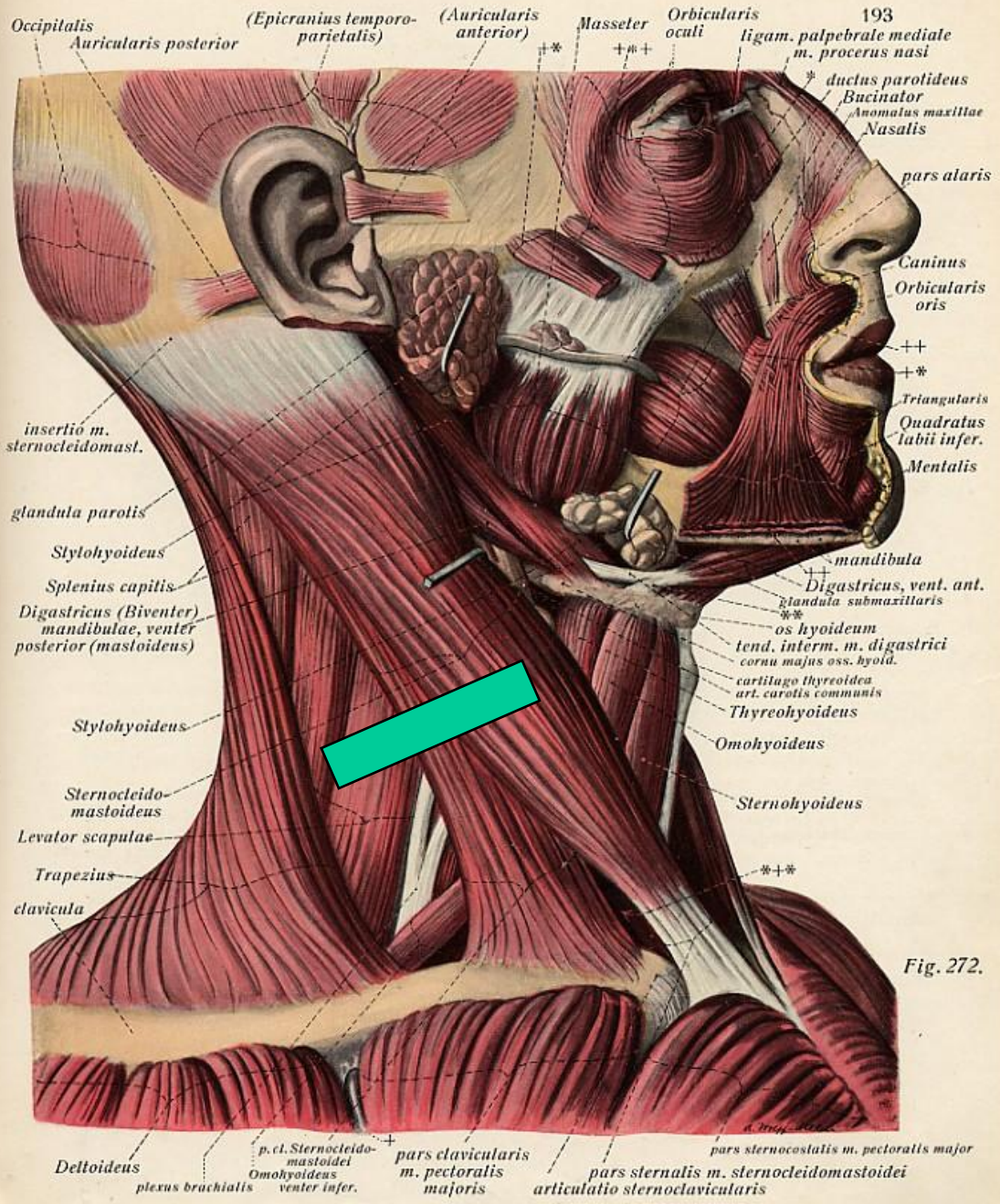
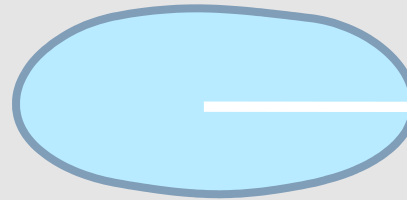


Fig. 272.


Sternomastoid




I.J.V.



Scalenus Posterior



Scalenus Medius





Scalenus Anterior




Brachial Plexus

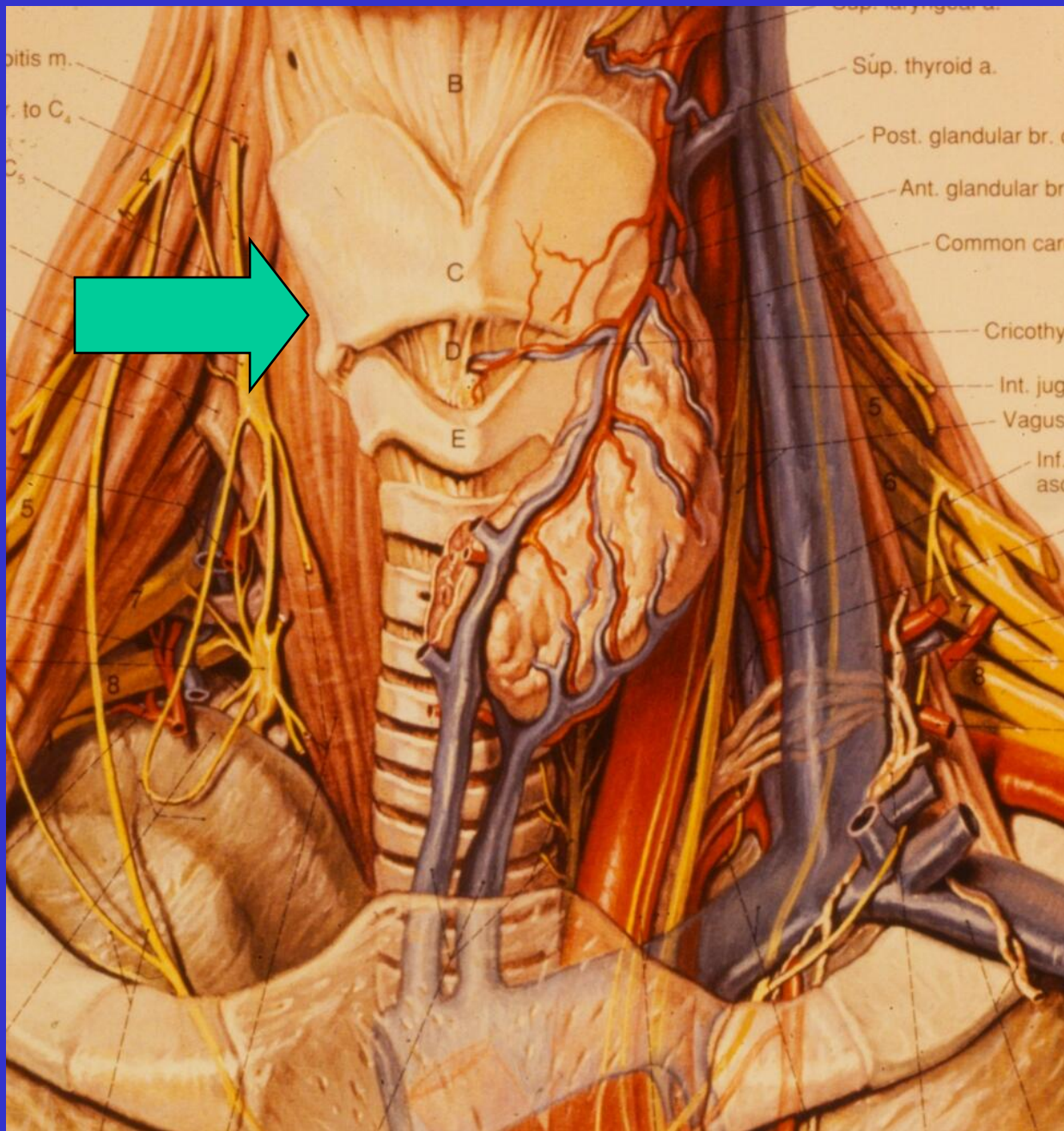
Trapezius



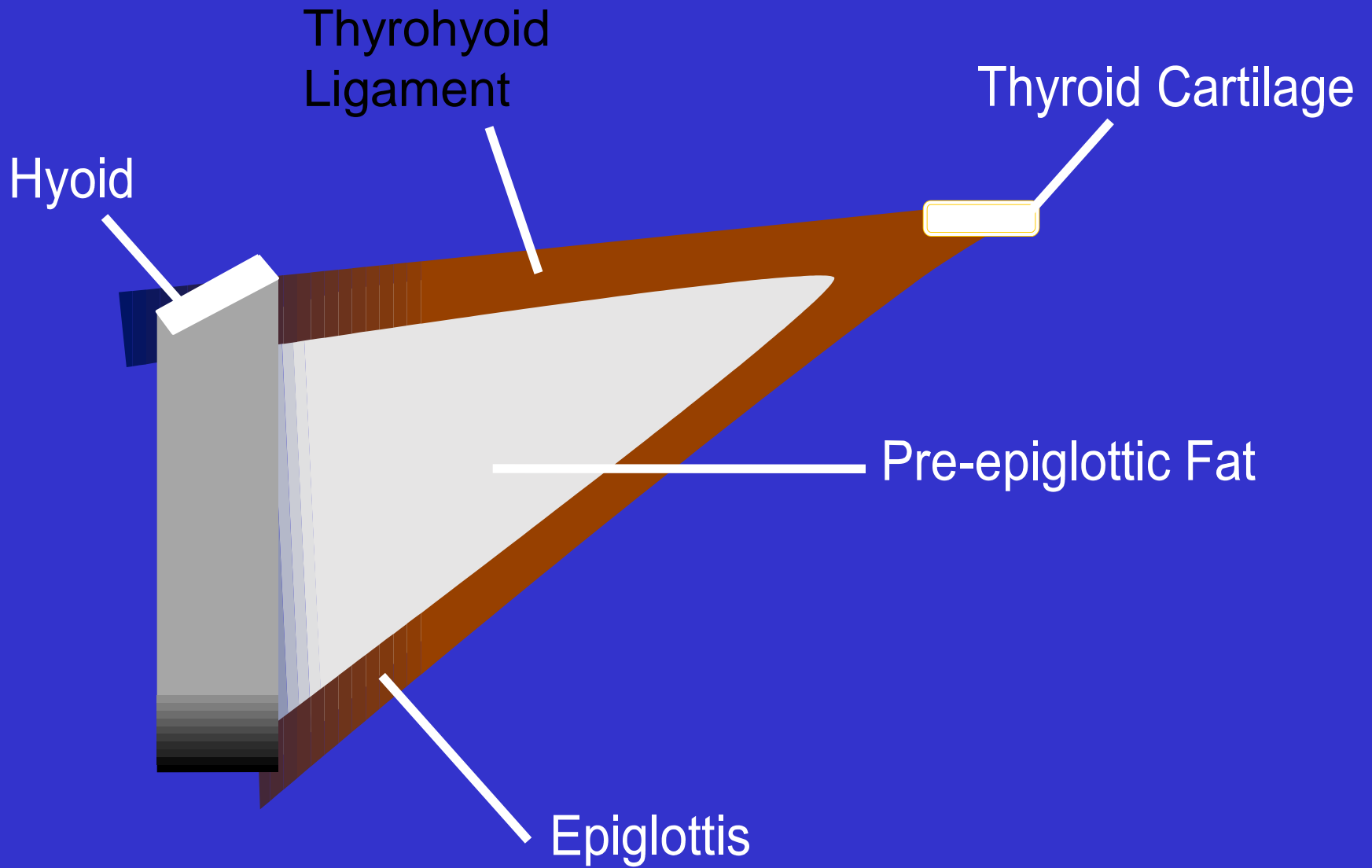
Levator  
Scapulae

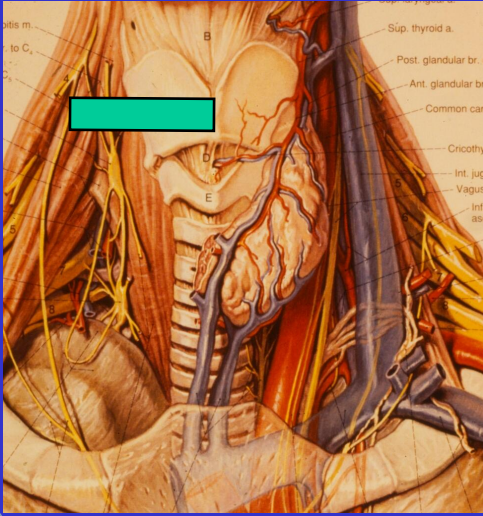



Scalenus  
Posterior

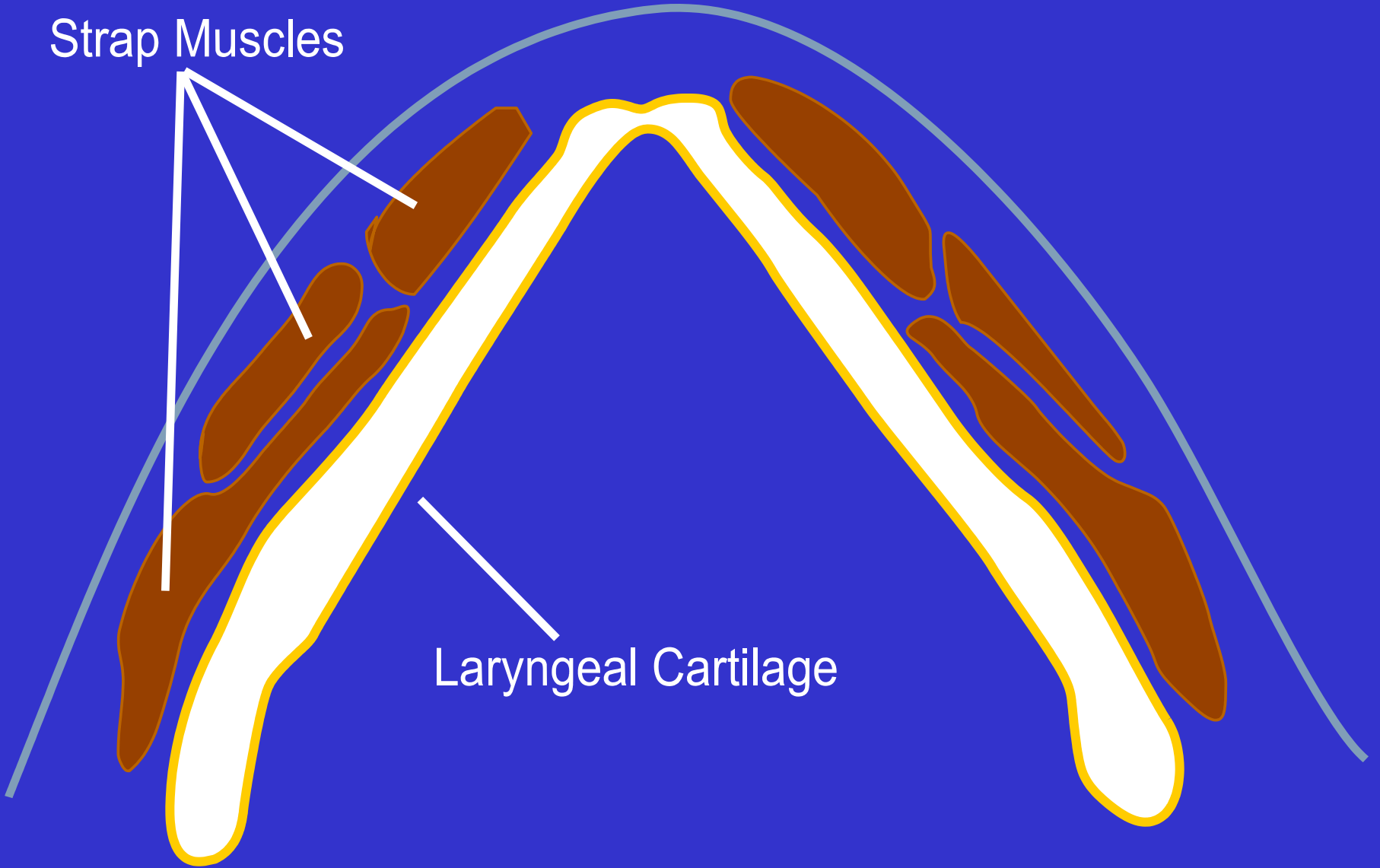








Strap Muscles



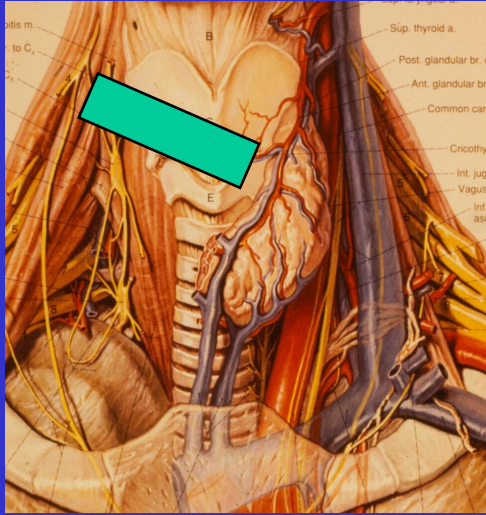

Laryngeal Cartilage

Strap Muscles

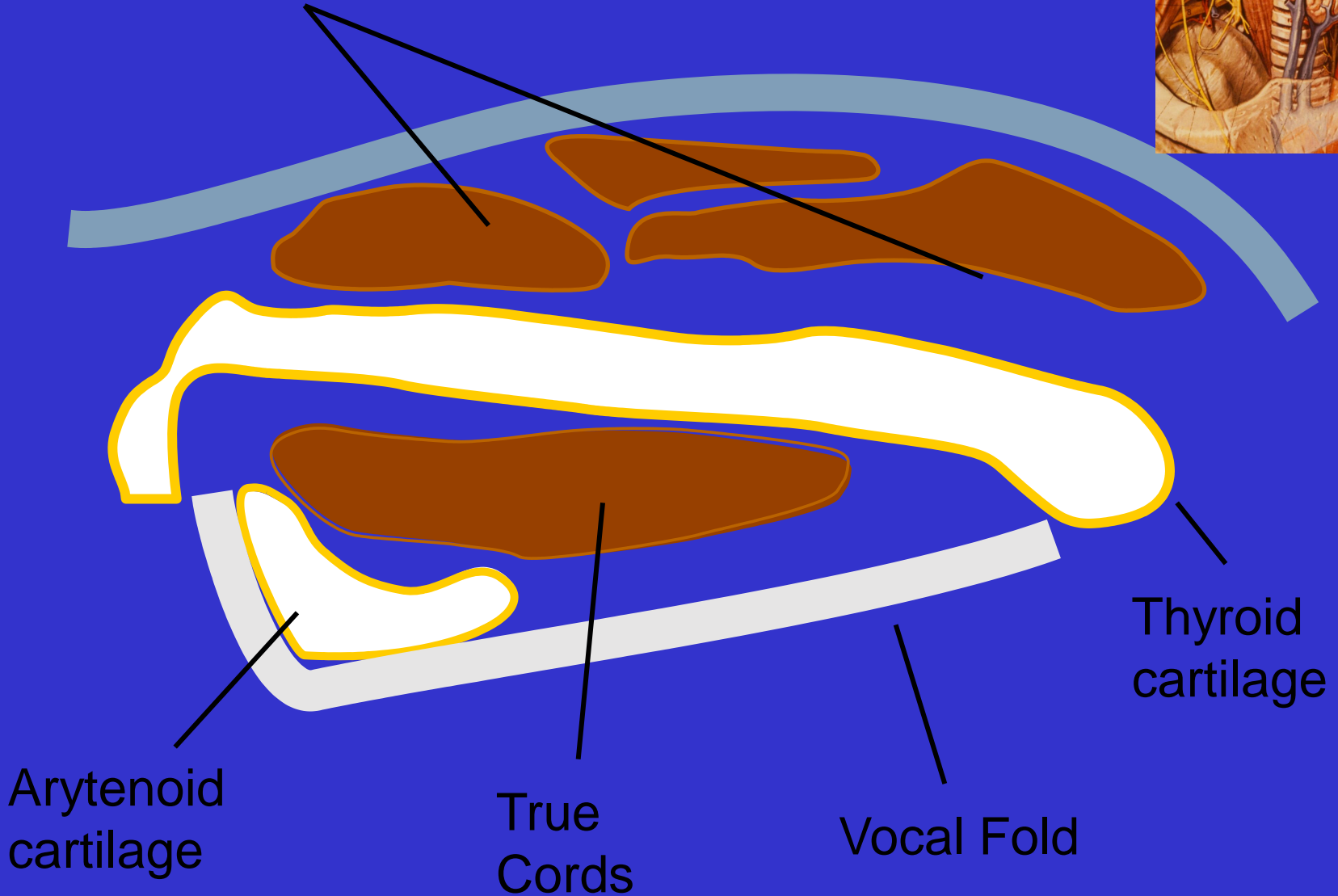
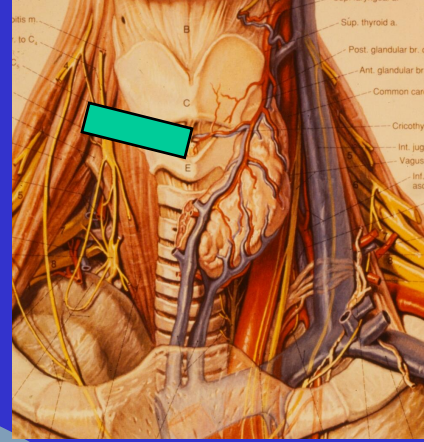
Thyroid cartilage

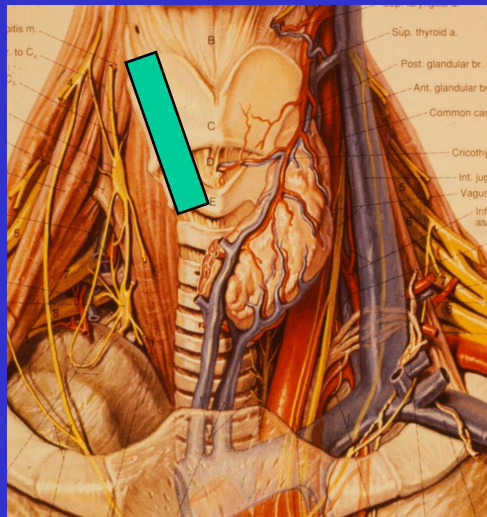

Paraglottic Fat

Vocal Fold



# Strap Muscles

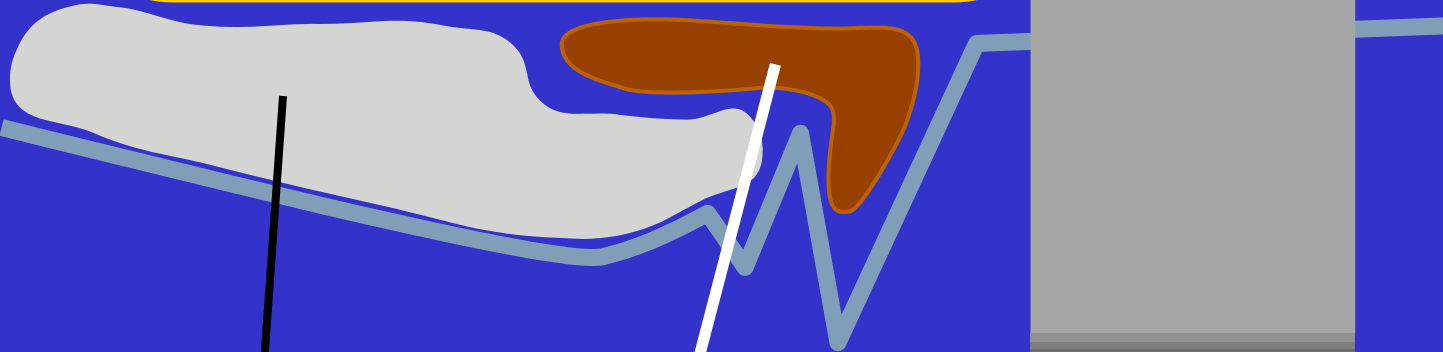





Strap Muscle

Thyroid  
Cricoid

} Cartilage



Intrinsic Muscle

Paraglottic Fat

